

The Mau-Reverdin Osteotomy: A Short-Term Retrospective Analysis

Nicolas Arcuri, DPM, AACFAS¹, Tzvi Bar-David, DPM, FACFAS², Simcha Pollack, PhD³



¹ Podiatrist, Department of Surgery, Jackson Madison County General Hospital, Jackson, TN

² Director of Podiatric Surgery, Department of Orthopedics, New York Presbyterian Hospital-Columbia University Campus, New York, NY

³ Professor, Computer Information Systems and Decision Sciences, St. John's University, Queens, NY

ARTICLE INFO

Level of Clinical Evidence: 4

Keywords:

bunion
 unionectomy
 hallux abductovalgus
 Mau
 osteotomy
 Reverdin

ABSTRACT

We reviewed 33 consecutive Mau-Reverdin osteotomies in 23 patients performed for correction of hallux abducto valgus from November 2010 to May 2013. All patients were followed up and evaluated for a mean of 401 days and median of 360 days after surgery. In each foot, the preoperative first intermetatarsal angle, hallux abductus angle, and proximal articular set angle were obtained. The mean correction of these angles was as follows: intermetatarsal angle $10.5^\circ \pm 3.31^\circ$, hallux abductus angle $24.4^\circ \pm 8.8^\circ$, and proximal articular set angle $28.39^\circ \pm 11.2^\circ$. Furthermore, we evaluated for metatarsus elevates, and no statistically significant first metatarsal elevation was present in any of the 33 feet ($p < .0001$). Additionally, 21 of the 33 feet (63.6%) were available for first metatarsophalangeal joint American Orthopaedic Foot and Ankle Society scale score evaluation. The mean preoperative score was 25.5 ± 16.7 . After correction, the mean American Orthopaedic Foot and Ankle Society scale score had increased to 95.4 ± 5.7 . All these differences were statistically significant ($p < .0001$), and the patients had a very high level of satisfaction. In all 33 feet, no deep infection, malunion, nonunion, avascular necrosis of the first metatarsal, or hardware failure developed. One patient developed hallux varus deformity. The Mau-Reverdin osteotomy is a very effective and reproducible procedure that successfully corrects large bunion deformities and provides patients with a high level of satisfaction and a low complication rate.

© 2016 by the American College of Foot and Ankle Surgeons. All rights reserved.

Hallux abducto valgus (HAV) is a complex deformity. It has been widely accepted that a combination of bone and soft tissue procedures is required to obtain the optimal correction. A multitude of osteotomies and procedures has been described for deformities in which a large intermetatarsal angle (IM) angle exists, and/or an articular deviation is present. Osteotomies of the first metatarsal can be divided into 3 types: translational, wedge, and rotational. These osteotomies are most commonly performed at 3 locations to correct for the bunion deformity. These are at the head, the shaft, and the proximal metatarsal, including the metatarsal cuneiform joint (1).

In cases in which a capital translational osteotomy, such as a chevron, is no longer sufficient for correction, opinions have varied regarding which osteotomy would be best. Many have suggested the Lapidus procedure, which is a fusion of the first metatarsal–cuneiform joint. The Lapidus procedure can stand alone as a positional fusion procedure or can be performed with wedge resection. Metatarsal base wedge-type osteotomies, such as a closing or opening type wedge, are

also options (2–4). Others have advocated the scarf osteotomy, which is a mid-shaft translational procedure (5). Additionally, crescentic osteotomies, which are rotational, have been described (6).

In our practice, we often choose the Mau and Reverdin procedures, in combination, to achieve the necessary correction. We choose this combination of osteotomies for several reasons: ease of execution, intrinsic stability to ground reactive forces, ease of fixation, and avoidance of fusion of the first metatarsal–cuneiform joint. Additionally, the combination of these procedures will achieve decompression of the metatarsophalangeal joint (MPJ) with minimal shortening, allowing for increased range of motion of the first MPJ and relaxation of the bowstring and abducted extensor hallucis longus tendon (7–10). In addition to osteotomies, an aggressive soft tissue release is performed in all the patients. See the surgical technique description for details.

The Mau osteotomy began as a modification of the Ludloff procedure in the early 20th century. The Ludloff osteotomy was not fixated, and the Mau osteotomy challenged its inherent instability to ground reactive forces, which would cause displacement of the dorsal fragment (Fig. 1A and B). Mau described the reverse osteotomy, from dorsally and distally to plantarly and proximally, producing a stable rigid dorsal shelf to resist the ground reactive forces (Fig. 1C and D). Most recently, this procedure was modified by a longer proximal cut entering the metatarsal bone to allow fixation with compression screws (8).

Financial Disclosure: None reported.

Conflict of Interest: None reported.

Address correspondence to: Nicolas Arcuri, DPM, AACFAS, Department of Surgery, Jackson Madison County General Hospital, 657 Skyline Drive, Suite A, Jackson, TN 38305.

E-mail address: nckarcuri@yahoo.com (N. Arcuri).

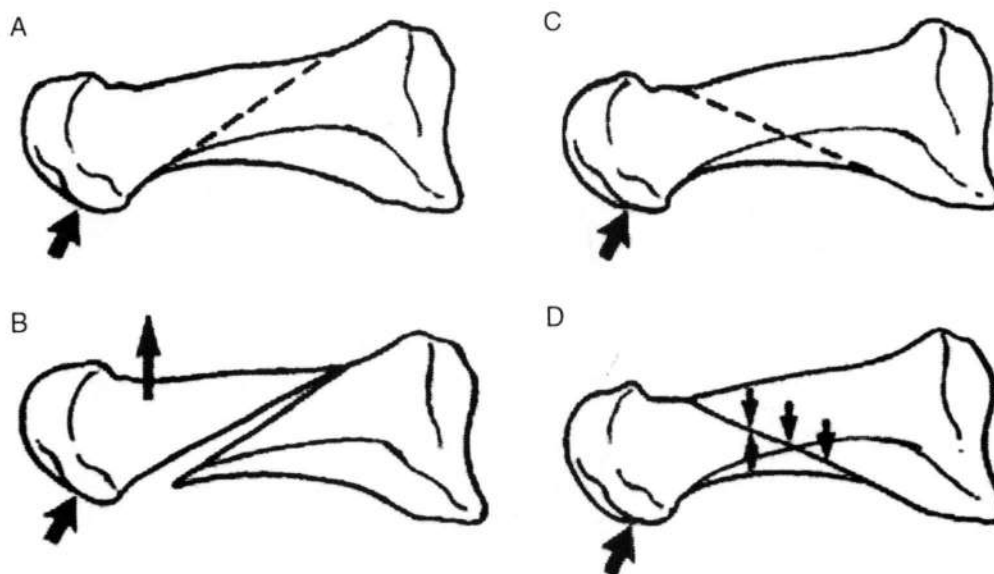


Fig. 1. Effect of ground reactive forces (A) on Ludloff osteotomy (arrow). (B) Note dorsal displacement of the capital fragment with the Ludloff osteotomy in response to ground reaction force (arrows). (C) Effect of ground reactive forces on Mau osteotomy (arrow). (D) Note the dorsal shelf of Mau osteotomy prevents dorsal displacement of the capital fragment and promotes stability in response to ground reaction forces (small arrows).

The Reverdin osteotomy was first described for use in the bunion deformity by Reverdin in 1881. It was originally described as a procedure in which a wedge of bone was resected proximally to the articular surface of the head of the first metatarsal. This procedure results in correction of the proximal articular set angle (PASA). The Reverdin modification used is that of Laird. It was developed by Laird in 1977. Its added modification is performed by cutting through the apex of the wedge, which allows for lateral translation of the capital fragment and protection of the sesamoid, while allowing correction of the IM angle in addition to the PASA (11).

Hence, we use a combination of a rotational (Mau) and translational (Reverdin) osteotomy to achieve optimal correction. In contrast to midshaft translational osteotomies, which can cause troughing, rotational midshaft osteotomies have full bone-to-bone contact at the area of the proximal rotational axis, which does not allow for troughing. Furthermore, with primarily rotational IM closure, relatively little shortening occurs compared with proximal wedge-type osteotomies (7,8,12). Osteotomies exist that can also have the benefit of lengthening the metatarsal, such as the opening wedge-type osteotomy (13).

Patients and Methods

We analyzed 33 consecutive Mau-Reverdin osteotomies in 23 patients performed for correction of hallux abducto valgus (HAV) from November 2010 to May 2013. The mean patient age was 48 ± 15 (range 16 to 70) years. All 23 patients (100%) were women. All patients were followed up and evaluated for a mean of 401 ± 227 days after surgery. In each foot, the preoperative first intermetatarsal (IM) angle, hallux abductus angle (HAA), and PASA were obtained. Furthermore, we evaluated for metatarsus elevatus by examining the lateral weightbearing films, noting the relationship of the first metatarsal to the dorsal second metatarsal cortex at the level of the distal metaphysis. If more than one third of the first metatarsal was above the second metatarsal cortex, we considered this first metatarsal elevation. For the purposes of the present study, all radiographic measurements were performed on weightbearing radiographs by 1 of us (N.A.A.). The qualification criteria for the patients included in the study were as follows: (1) performance of a Mau-Reverdin osteotomy; (2) surgery performed from November 2010 to May 2013; (3) procedures performed by the same surgeon (T.B.D.). No age restrictions were in place, and revision surgery was not excluded. To determine which patients had undergone Mau-Reverdin osteotomy, a search was performed using the Common Procedural Terminology code 28299 (double osteotomy for correction of hallux valgus) within the billing software.

The surgical technique consists of a dorsal linear skin incision made medially and parallel to the extensor hallucis longus tendon. The incision is deepened to the periosteum and capsule, where an inverted medial L capsulotomy is performed. The capsule and full-thickness periosteum are reflected dorsally and plantarly, exposing

the plantar surface of the metatarsal down to the base, where the flare will be palpable and visualized. Next, the medial metatarsal exostosis is resected with a sagittal saw. A first interspace soft tissue release is achieved with release of the conjoined adductor hallucis tendon and release of the fibular sesamoid metatarsal suspensory ligament. The hallux is then manipulated in the direction of maximum allowable adduction to release any further adhesions or scarring within the first interspace holding the toe in the abducted position. The fibular sesamoid is palpated to ensure it can be realigned under the metatarsal as the hallux is repositioned medially. Next, the foot is repositioned on the table, with the lateral aspect against the operative table and the dorsal, medial, and plantar aspect of the first metatarsal exposed and facing dorsally. We minimize lateral and dorsal dissection of the soft tissues surrounding the metatarsal head, thus protecting the blood flow to the head. A sagittal saw is then used to create the Mau osteotomy with a single cut starting distally and dorsally and ending proximally and plantarly. The osteotomy is started approximately 1.5 to 2 cm proximal to the first MPJ, extending into the shaft, and ending approximately 1 to 1.5 cm distal to the first metatarsal-cuneiform joint (Fig. 2). This creates a fixed dorsal shelf and a plantar segment that includes the metatarsal head. We attempt to have the cut parallel the weightbearing surface. The cut should be sufficiently long enough to allow for appropriate fixation, and it can extend into the metatarsal base at its flare, and, even if necessary, to the metatarsal at the edge of the medial cuneiform joint. Maintaining this position, the osteotomy is stabilized with a bone clamp, and the foot is then repositioned to face dorsally on the table. A 0.45-in. Kirschner wire is drilled at the proximal aspect, perpendicular to the osteotomy from dorsally to plantarly to provide stabilization and a rotational axis. While accomplishing this, it is important to maintain the original length of the first metatarsal. Next, the clamp is removed, and the plantar shelf, which contains the head of the metatarsal, is rotated laterally under the stable dorsal shelf to reduce the IM angle. If desired, the metatarsal can be slightly lengthened or shortened, if clinically indicated, by sliding the plantar segment proximally or distally (see the discussion section for the effect on shortening with additional Reverdin). The fluoroscope is used intraoperatively to visualize the correction. Using a



Fig. 2. Medial view of the Mau osteotomy.

bone clamp, the osteotomy is compressed to stabilize the metatarsal in its corrected position, and a secondary Kirschner wire is inserted to help maintain this corrected position. If further correction is necessary, it can be achieved with additional rotation of the Mau if possible, without overcorrection or with a Reverdin osteotomy (see the discussion section for the effect of PASA with the Mau osteotomy). Next, fixation is accomplished with 2 or 3 lag screws. We usually use 2.7- to 4.0-mm screws. Sometimes, 2.0-mm screws are also used, especially in the more distal aspect of the osteotomy. The screws are oriented dorsally to plantarly and are usually oriented perpendicularly to the osteotomy along its length (Fig. 3). The redundant medial bone shelf is then smoothed with a power burr. At this point, attention is directed to the head of the first metatarsal and, if articular deviation is present and/or further IM correction is required, a Reverdin-Laird osteotomy is performed, with a cut paralleling the sesamoids plantarly and a wedge dorsally, with its apex laterally. To correct for the PASA, the 2 cuts of the wedge are made with the distal cut parallel to the articular cartilage and the proximal cut perpendicular to the metatarsal shaft. Once the wedge is closed, the saw is then pushed through the lateral cortex, and the head is translated to correct the IM angle to its fullest. The fluoroscope is used to confirm the position. The osteotomy is then fixated with a single 3.0-mm headless cannulated screw placed from dorsally and proximally to plantarly and distally, ensuring that it does not exit through the articular cartilage into the joint space. The surgical site is then closed in layers. The capsule can be further used for correction of the abducted hallux position by removing a portion of the capsule at the base of the L and suturing the capsule tightly. This is especially useful in the most exaggerated HAAs. Care must be taken to not have the tibial sesamoid peek medial to the metatarsal head, because this could later promote the formation of a varus deformity. The intraoperative fluoroscope is used again to visualize the sesamoid location and the congruity of the first MPJ. The foot is placed in a non-weightbearing cast for the first week and then in a non-weightbearing posterior splint for the next 3 weeks to allow for passive ankle and first MTP range of motion. On removal of the posterior splint, the patient is allowed to ambulate in either a controlled ankle motion boot for the next several weeks or directly into a sneaker, depending on the findings from the healing assessment.

Results

A total of 33 feet in 23 patients were evaluated. Of these, 32 feet (97%) underwent a combined Mau-Reverdin osteotomy, and 1 foot

(3%) underwent only the Mau procedure. All the medical records were evaluated for the radiographic findings and complications. Additionally, of the 23 patients, 14 patients (60.1%), representing 21 feet (63.6%), were available for pre- and postoperative American Orthopaedic Foot and Ankle Society scale (AOFAS) scores.

The mean follow-up period was 401 ± 227 (range 129 to 1201) days. The preoperative mean IM 1-2 and HAV angle was $15.9^\circ \pm 2.6^\circ$ (range 12° to 24°) and $36.9^\circ \pm 6.1^\circ$ (range 23° to 50°), respectively. The postoperative mean IM 1-2 angle and HAA was $5.4^\circ \pm 2.92^\circ$ (range 1° to 12°) and $12.6^\circ \pm 6.4^\circ$ (range -2° to 22°), respectively. The preoperative and postoperative PASA was $34.4^\circ \pm 9.7^\circ$ (range 15° to 52°) and $6.1^\circ \pm 5.3^\circ$ (range -3° to 18°), respectively. The preoperative and postoperative AOFAS scale scores were 25.5 ± 16.7 (range 5 to 52) and 95.4 ± 5.7 (range 82 to 100), respectively (Table). Using a 2-tailed *t* test, all variables were statistically significant at $p < .0001$.

No metatarsal elevation was present in any of the 33 feet using the evaluation method we have described. Additionally, on clinical and radiographic review, no complications of nonunion, malunion, hardware failure, avascular necrosis, or infection had developed. One patient developed postoperative radiographic hallux varus with an HAA of -2° , a PASA of -3° , and an IM angle of 4.

Nine patients (39%) were unavailable for long-term follow-up and hence were unable to participate in the AOFAS scale evaluation. Radiographically, at an approximately 1-year follow-up point, the entire study population had maintained their correction.

Discussion

Many variations of osteotomies are available to the surgeon for correction of moderate to severe HAV deformities. When choosing a

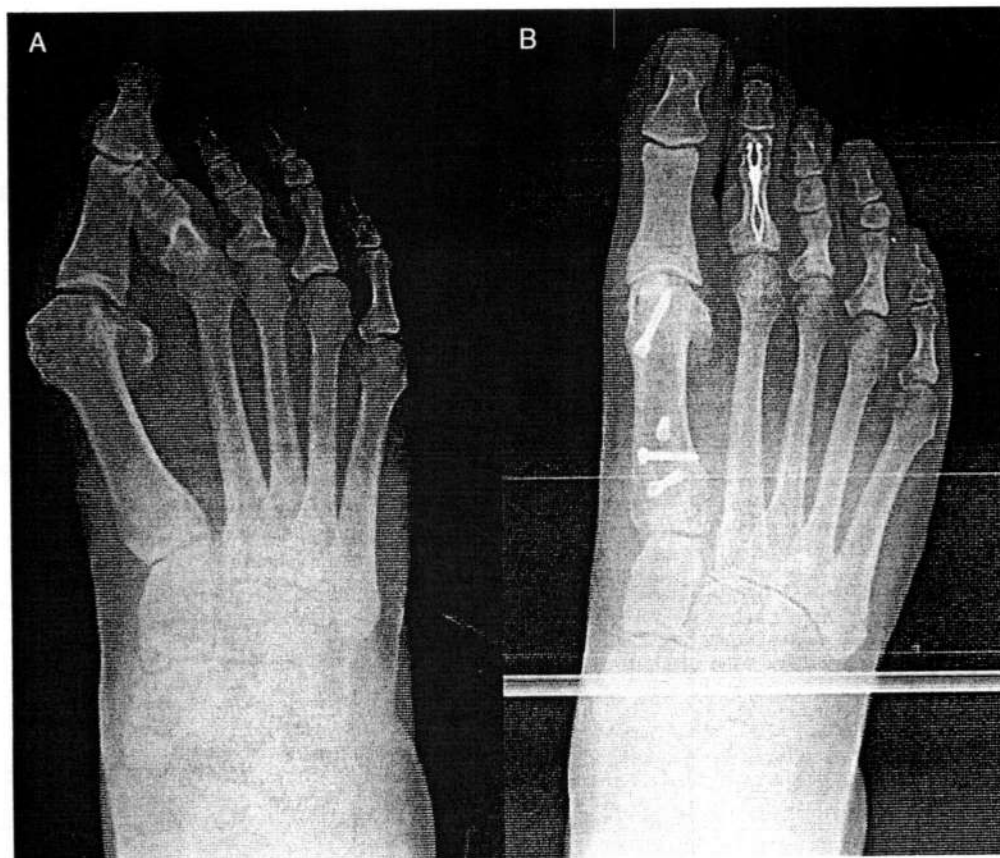


Fig. 3. (A) Preoperative and (B) postoperative radiographs with internal fixation placement of a Mau-Reverdin osteotomy at 1201 days postoperatively.

Table
Measured variables (N = 33 feet in 23 patients)

Variable	Mean	Minimum	Maximum
Age (y)	48 ± 15	16	70
Follow-up (d)	401 ± 227	30	1201
Preoperative IMA (°)	15.9 ± 2.6	12	24
Postoperative IMA (°)	5.4 ± 2.9	1	12
ΔIMA (°)	10.5 ± 3.3	3	18
Preoperative HAA (°)	37 ± 6.2	23	50
Postoperative HAA (°)	12.6 ± 6.4	-2	22
ΔHAA (°)	24.4 ± 8.8	11	44
Preoperative PASA (°)	34.4 ± 9.6	15	52
Postoperative PASA (°)	6.1 ± 5.4	-3	18
ΔPASA (°)	28.3 ± 11.2	4	50
Preoperative AOFAS score	25.5 ± 16.7	5	52
Postoperative AOFAS score	95.4 ± 5.7	82	100
ΔAOFAS score	70 ± 15.7	46	95

Abbreviations: AOFAS, American Orthopaedic Foot and Ankle Society; HAA, hallux abductus angle; IM, Intermetatarsal; PASA, proximal articular set angle.

procedure, it is important to be able to consistently achieve proper correction and minimize the chance of complications. Previous studies have demonstrated that both soft tissue release and a proximal osteotomy are necessary for correction of larger deformities (1).

The Mau procedure is a rotational osteotomy that does not allow for troughing compared with the scarf osteotomy, which is translational (14). Furthermore, the Mau has a stable dorsal shelf, preventing elevation, which is a common concern with crescentic and wedge osteotomies (6).

In their evaluation of the Mau versus the crescentic osteotomy, Hyer et al (7) reported a 4.2% nonunion rate with the Mau osteotomy. Neither Neese et al (8), nor ourselves, encountered any cases of nonunion. Both Hyer et al (7) and Neese et al (8) used a more conservative postoperative weightbearing protocol. In the study by Neese et al (8), the patients were allowed weightbearing as tolerated in either a walking boot after the first postoperative visit and Hyer et al (7) allowed their patients to weight bear after the first postoperative visit in a surgical shoe. Hyer et al (7) also reported 2.00 mm of shortening with the Mau procedure, which was statistically significantly better than they found with the crescentic osteotomy.

The Lapidus procedure and base osteotomies can create shortening, as well as elevation, of the distal metatarsal segment (4,12). Furthermore, concern exists for nonunion of the first metatarsal cuneiform joint after performing the Lapidus procedure, with earlier studies finding the mean to be approximately 10% (15–17). However, with newer techniques in internal fixation, the nonunion rate has decreased to <5% (18–21). Another advantage of the Mau osteotomy is that it is statistically more resistant to fatigue than other proximal osteotomies (22).

Many studies have shown the benefit of the large IM angle and HAA correction abilities of the Mau osteotomy (7,8,23), including the study by Glover et al (9), with corrections of $9.80^\circ \pm 2.43^\circ$ and $12.96^\circ \pm 7.15^\circ$, respectively. Our results were similar, with correction of the IM angle of $10.5^\circ \pm 3.31^\circ$ and HAA of $24.4^\circ \pm 8.8^\circ$. These results match those from an earlier study by Bar-David and Greenberg (24), with an IM angle and HAA correction of 10.5° and 23.5° , respectively.

It is important to be cognizant and to remember the effect of the Mau procedure on the PASA. Because it is a rotational osteotomy, as the IM angle is being corrected, the PASA will only increase further from its original deviation. As the plantar segment encompassing the head rotates laterally in an arch, the lateral tilt of the articular cartilage will be increased. Furthermore, the metatarsal head can tilt excessively. Thus, an optimal correction exists with the Mau procedure to create a neutrally positioned first metatarsal. If

additional IM angle correction is necessary, this would require the translation of the Reverdin procedure. Hence, the combination of these 2 procedures will produce the optimal correction in the most severe deformities. Although some shortening of the metatarsal will occur when performing the Reverdin, we have found this to be minimal, because we do not correct the Mau osteotomy past the first metatarsal neutral position. Usually, we have not found it necessary to lengthen the first metatarsal. However, if clinically indicated by the surgeon, this can be accomplished by sliding the plantar segment forward slightly as described in the Patients and Methods section.

Our results for the mean preoperative and postoperative PASAs of $34.4^\circ \pm 9.7^\circ$ (range 15° to 52°) and $6.1^\circ \pm 5.3^\circ$ (range -3° to 18°), respectively, show that the use of the Reverdin combined with the Mau osteotomy can successfully reduce the IM angle and still allow for joint congruity.

In fixing the Mau procedure, thus far, we have used screws. Additional study is needed to evaluate whether the combination of screws and plating offers an advantage.

In conclusion, a multitude of procedures are available for correction of the advanced HAV deformity. Ultimately, the procedure of choice should be that with which the surgeon is most comfortable and that results in satisfactory correction of the deformity. Our review has demonstrated that the Mau and Reverdin-Laird osteotomies, when used in combination, result in a stable, reliable, and reproducible correction, with high patient satisfaction and a low complication rate. This procedure has many advantages for correction of the advanced HAV deformity.

References

- Boberg S. Evaluation and procedural selection in hallux valgus surgery. In: *McGlamry's Comprehensive Textbook of Foot and Ankle Surgery*, ed 4, pp. 245–249, edited by JJ Southerland, Lippincott Williams & Wilkins, Philadelphia, 2012.
- Ruch JA. Current use of the oblique base wedge osteotomy in hallux valgus surgery. In: *Reconstructive Surgery in the Foot and Leg Update*, Podiatry Institute Publishing, Tucker, GA, 1994, pp. 128–132.
- Trethowan J. Hallux valgus. In: *A System of Surgery*, ed 3, pp. 1046–1049, edited by C Choice, PB Hoer, New York, 1923.
- Lapidus PW. The operative correction of the metatarsus primus varus in hallux valgus. *Surg Gynecol Obstet* 58:183–191, 1934.
- Weil LS. Scarf osteotomy for correction of hallux valgus: historical perspective, surgical technique, and results. *Foot Ankle Clin* 5:559–580, 2000.
- Cohen M, Roman A, Ayers M, Freedline A. The crescentic shelf osteotomy. *J Foot Ankle Surg* 32:204–226, 1993.
- Hyer CF, Glover JP, Berlet GC, Philbin TM, Lee TH. A comparison of the crescentic and Mau osteotomies for correction of hallux valgus. *J Foot Ankle Surg* 47:103–111, 2008.
- Neese DJ, Zelichowski JE, Patton GW. Mau osteotomy: an alternative procedure to the closing abductory base wedge osteotomy. *J Foot Surg* 28:352–362, 1989.
- Glover JP, Hyer CF, Berlet GC, Lee TH. Early results of the Mau osteotomy for correction of moderate to severe hallux valgus: a review of 24 cases. *J Foot Ankle Surg* 47:237–242, 2008.
- Timothy EK. Phalangeal osteotomy versus first metatarsal decompression osteotomy for the surgical treatment of hallux rigidus: a prospective study of age matched and condition matched patients. *J Foot Ankle Surg* 44:2–12, 2005.
- Beck E. Modified Reverdin technique for hallux abducto valgus (with increased proximal articular set angle of the first metatarsal phalangeal joint). *J Am Podiatry Assoc* 64:657–666, 1974.
- Schuberth T, Reilly CH, Gudas CJ. The closing wedge osteotomy: a critical analysis of the first metatarsal elevation. *J Am Podiatry Assoc* 74:13–25, 1989.
- Budny AM, Masadeh HB, Lyons MC, Frania SJ. The opening base wedge osteotomy and subsequent lengthening of the first metatarsal: an in vitro study. *J Foot Ankle Surg* 48:662–667, 2009.
- Easley MW, Darwish HH, Schreyack DW, DeOrto JK, Trnka HJ. Hallux valgus: proximal first metatarsal osteotomies. In: *Internal Advances in Foot and Ankle Surgery*, pp. 11–25, edited by A Saxena, Springer, London, 2012.
- Sangeorzan BJ, Hansen ST. Modified Lapidus procedure for hallux valgus. *Foot Ankle* 9:262–266, 1989.
- Myerson M, Allon S, McGarvey W. Metatarsocuneiform arthrodesis for management of hallux valgus and metatarsus primus varus. *Foot Ankle* 13:107–115, 1992.
- Cantanzariti AR, Mendicino RW, Lee MS, Gallina MR. Modified Lapidus arthrodesis: a retrospective analysis. *J Foot Ankle Surg* 38:322–332, 1999.